

Analysis of epidermal lipids in normal and atopic dogs, before and after administration of an oral omega-6/omega-3 fatty acid feed supplement. A pilot study

Iuliana Popa · Didier Pin · Nathalie Remoué ·
Bilal Osta · Sylvie Callejon · Emilie Videmont ·
Hugues Gatto · Jacques Portoukalian · Marek Haftek

Accepted: 12 July 2011 / Published online: 23 July 2011
© Springer Science+Business Media B.V. 2011

Abstract Alterations of the lipid expression in the skin of human and canine atopic subjects may be one of the key factors in the disease development. We have analyzed the ultrastructure of the clinically uninvolved skin of atopic dogs and compared it with the lipid composition of their tape-stripped stratum corneum (SC). The effect of a 2 month treatment of atopic dogs by food supplementation with a mixture of essential fatty acids was evaluated on skin samples taken before and after the treatment period. Electron microscopy revealed that the non-lesional skin of atopic dogs exhibited an abnormal and largely incomplete structure of the lamellar lipids with little cohesion between the corneocyte strata. The SC of atopic dogs was characterized by a significant decrease in the lipid content when compared to the healthy controls. Following oral supplementation with the mixture of essential fatty acids, the overall lipid content of the SC markedly increased. This feature was observed both with the free and, most importantly, with the protein-bound lipids (cholesterol, fatty acids and ceramides), the latter constituting the corneocyte-bound scaffold for ordinate organisation of the extracellular lipid bi-layers. Indeed, the semi-quantitative electron microscopy study revealed that the treatment resulted in a significantly improved organization of the lamellar lipids in the lower SC, comparable to that of the

I. Popa · N. Remoué · B. Osta · S. Callejon · J. Portoukalian · M. Haftek
Laboratory for Dermatological Research EA4169 “Normal and Pathological Functions of the Skin Barrier”, Université Lyon 1, Lyon, France

D. Pin · E. Videmont
Dermatology–Cancerology Unit, VêtAgro Sup Lyon Campus, Marcy L’Etoile, France

H. Gatto
Virbac SA, Carros, France

M. Haftek (✉)
Laboratoire de Recherche Dermatologique, EA4169, UCBL1, 8, Av. Rockefeller, 69373 Lyon, France
e-mail: marek.haftek@univ-lyon1.fr

Present Address:

I. Popa
UMR CNRS 8612, University of Paris XI, 92290 Châtenay-Malabry, France

healthy dogs. Our results indicate the potential interest of long-term alimentary supplementation with omega-6 and omega-3 essential fatty acids in canine atopic dermatitis.

Keywords Canine atopic dermatitis · Lipid analysis · Stratum corneum · Feed supplement · Dogs

Abbreviations

AD Atopic dermatitis
SC Stratum corneum
EFA Essential fatty acids

Introduction

According to the latest criteria, canine atopic dermatitis (AD) is defined as a genetically determined, allergic, inflammatory, and pruritic skin disorder, with characteristic clinical features, most commonly associated with IgE antibodies to environmental allergens (Willemsse 1986; Griffin and DeBoer 2001). It is a common condition estimated to affect 10–15% of the canine population. Clinical and immunological studies of canine AD suggest that canine AD is probably one of the closest animal models to human AD (Hillier and Olivry 2004). In humans, epidermal barrier dysfunction provoked by loss-of-function mutations in the filaggrin gene has been incriminated in the predisposition to develop AD (Sandilands et al. 2007; Jakasa et al. 2011). This was the first documented proof of implication of the altered permeability barrier in the pathogenesis of AD (Elias et al. 2008). However, abnormal lipid expression in the stratum corneum (SC) of uninvolved skin of AD patients has also been reported (Imokawa et al. 1991; Di Nardo et al. 1998; Macheleidt et al. 2002) and is likely to be another factor predisposing to the disease because its occurrence seems to be dissociated from the presence of filaggrin mutations (Jungerstedt et al. 2010). Indeed, a subgroup of canine AD can be defined that do not depend on the filaggrin gene mutations (O'Regan et al. 2010).

There is no clear-cut evidence published so far that canine AD is associated with defective filaggrin expression (Chervet et al. 2010). On the contrary, linkage studies in West Highland White Terriers indicate the absence of such correlation (Barros Roque et al. 2009). However, SC lipid abnormalities have been reported. Indeed, both continuity and overall thickness of the SC intercellular lipid lamellae, which are prerequisite for the proper barrier function, were significantly decreased in the non-lesional skin of dogs with AD (Inman et al. 2001; Piekutowska et al. 2008). These morphological findings have been supported by biochemical analyses showing abnormal composition of the SC lipids, and more specifically ceramides, in AD dogs (Reiter et al. 2009; Shimada et al. 2009; Popa et al. 2011, Popa et al., (in preparation)) and by functional assays testifying to an increased permeability of the skin barrier in this disease (Shimada et al. 2009). Once defined as a possible causative factor in AD, SC lipids became the target of therapies aimed at improving the epidermal barrier function. Topical application of a mixture of lipids necessary for restructuring of the SC lipid lamellae has been successfully used in dogs and resulted in both structural and clinical improvement (Piekutowska et al. 2008; Popa et al. 2011a, b). A feed supplement containing essential fatty acids (EFA) and vitamin E has been designed to help restore the cutaneous integrity by normalizing the lipid metabolism and thus improving the quality of the lipids present in the skin. Its potential influence on the composition and structure of the SC intercellular lipids in AD dogs has been addressed in the present study.

Materials and methods

Animals

The study was conducted in compliance with the Procedures of Good Clinical Practice, as detailed in the European Commission Note.

Client-owned dogs with AD were eligible for inclusion in the study. The diagnostic of AD was made on the basis of a compatible history and fulfillment of the currently accepted clinical criteria proposed by Willemse (1986) and redefined by Favrot et al. (2010). All similar-appearing skin diseases with pruritus, such as sarcoptic mange, flea allergy dermatitis, bacterial pyoderma and *Malassezia* dermatitis were carefully ruled out, according to standard diagnostic and treatment methods. Dogs with an uncontrolled skin or auricular bacterial or fungal infection or with uncontrolled flea allergy dermatitis were excluded from the study. Before the beginning of the study, several local and systemic treatments have been interrupted. Parenteral administration of long-lasting corticosteroids, oral and topical administration of corticosteroids were discontinued for at least 8, 3 and 2 weeks, respectively; EFA administration was discontinued for at least 8 weeks; administration of antihistamines, cyclosporine or any other immunosuppressive drug was discontinued for at least 2, and 8 weeks, respectively.

Five dogs from different breeds clinically diagnosed with AD were selected for this study (Table 1). Five healthy adult female Beagle dogs (5–6 years of age) were used as the reference normal control.

Before the beginning of the study, several local and systemic treatments have been interrupted. Parenteral administration of long-lasting corticosteroids, oral and topical administration of corticosteroids were discontinued for at least 8, 3 and 2 weeks, respectively; EFA administration was discontinued for at least 8 weeks; administration of antihistamines, cyclosporine or any other immunosuppressive drug was discontinued for at least 2, and 8 weeks, respectively.

One chlorhexidine-containing shampoo of the skin lesional areas per week and the use of an ear cleanser without corticosteroid once or twice a week were authorized. In all dogs, a topical flea adulticide with minimum 1-month duration of activity was applied monthly throughout the study.

Owners of the dogs considered for inclusion in the study received detailed information on the study and provided a written informed consent.

The protocol was approved by the Animal Care and Use Committee of the Veterinary School of Lyon.

Treatment

The AD dogs were administered orally one dose of 4 ml per day for dogs of less than 10 kg or one dose of 8 ml per day for dogs with body weight over 10 kg of Megaderm®/EFA-Z® (Virbac S.A.; Carros, France), every day for 8 weeks. This feed

Table 1 Breed, age, and sex of the AD dogs studied

Breed	Age (years)	Sex
Labrador	9	F
Labrador	7	M
Coton	9	F
Golden Retriever	7	M
West Highland White Terrier	5	M

supplement is composed of the EFA, omega-6 (linoleic acid 350 mg/ml, gamma-linolenic acid 45 mg/ml) and omega-3 (eicosapentaenoic acid 25 mg/ml, docosahexaenoic acid 28 mg/ml), mixed 5:1 (v/v), and contains vitamin E 3.8 UI/mL. The 8 weeks of treatment were followed by 1 week of wash-out.

Skin analyses

To chemically and structurally analyse the epidermal lipids contained in the stratum corneum, before and after the administration of EFA and thus evaluate the effect of food supplementation, the stratum corneum was harvested by sequential tape-stripping and skin biopsies were performed in the dogs before the study and after 1 week of wash-out. As the study was aimed at the evaluation of clinically non-involved skin, we have chosen the lateral thorax region, which is less frequently involved during canine AD, for comparisons between AD and control groups.

Chemical analysis of the SC lipids

Consecutive adhesive tape-strips (Scotch® Magic™ tape; 3M, Cergy-Pontoise, France) were applied on the same area of non-lesional skin at the lateral aspect of the thorax. Before tape stripping, hairs in the area were carefully clipped with a shaving machine to the length of <2 mm. The tape was pressed to the skin with fingertips for 5 s. before rapid removal. Approximately 12 consecutive strips per area were needed to reach the viable epidermis characterized by a glistening skin surface.

SC lipids were extracted from tape strips using previously described methods (Popa et al. 2010, 2011a, b). Briefly, hexane/isopropyl alcohol mixture (4:1, v/v) was used to release the corneocytes from tape strips. Free intercellular lipids were extracted using chloroform/methanol (2:1 v/v mixture, two times) and then methanol alone (Extraction I). The cell pellet resulting from this first extraction was subjected to mild saponification with 0.1N KOH in methanol/water (10:1 v/v) for 2 h at 50°C (Wertz et al. 1989). After neutralization with 1N HCl, the protein residue was recovered by centrifugation and assayed by the Coomassie blue/Bradford method, whereas the lipids released from the cornified envelopes were harvested from the supernatants using phase separation after addition of distilled water and chloroform in appropriate proportions (Extraction II). Free (FL) and protein-bound lipids (PB) from each extraction were recovered by solvent evaporation, taken up in 0.5 mL of diethylether and separated into different classes on a LC-NH₂ silica gel column (Supelco; L'Isle d'Abeau, France). All fractions were evaporated to dryness under nitrogen atmosphere and analysed with high performance thin layer chromatography. To this end, the lipid samples applied on silica gel plates were migrated in the following solvent systems suitable for each lipid class: hexane–diethylether–acetic acid 70:30:1 (by volume) for neutral lipids and fatty acids; chloroform–methanol 50:3 (v/v) for ceramides. The lipids were visualized by charring for 5 min at 150°C after spraying with a reagent made of 3% cupric acetate in 8% phosphoric acid. Fractions containing ceramides were pooled and hydrolysed to release the long-chain bases, thus allowing quantification of shingolipids by the fluorescamine method (Naoi et al. 1974). Fractions containing cholesterol and fatty acids were also pooled. The distribution of components was determined by scanning densitometry with a CS-930 Chromatoscan (Shimadzu; Kyoto, Japan). For definition of ceramide subclasses we have referred to the nomenclature defined by Motta et al. (1993).

Quantitative results obtained on normal and atopic canine SC were compared using Mann–Whitney test, $P \leq 0.05$ being accepted as significant.

Structural analysis of the SC lipids

Punch biopsies (6 mm) were taken, under local anaesthesia, from a non-lesional zone of the lateral aspect of the thorax, next to the area of tape-stripping. Skin fragments were cut into small blocks and fixed in 1% glutaraldehyde/4% paraformaldehyde in phosphate buffered saline (PBS, pH 7.4) for 24 h. After washings in PBS, some blocks were post-fixed in 1% osmium tetroxide, the others in 0.5% ruthenium tetroxide for 2 h. All blocks were further washed in PBS, dehydrated in graded ethanol series, impregnated with and embedded in Epon resins according to standard procedures. Ultrathin sections counterstained with uranyl acetate and lead citrate were observed in a transmission electron microscope at 60 kV. Digital micrographs of the lowermost stratum corneum compactum were taken at 60,000x and 125,000x and analyzed using camera-dedicated software (AnalySIS, Olympus Soft Imaging Solutions; Hamburg, Germany). Specifically, we measured the section surface of the SC extracellular spaces and, within these areas, defined the surface occupied by extracellular lipids organized in bi-layers. Several optical fields on every specimen were thus analyzed and the results were expressed as mean percentage of the extracellular space occupied by the structured lipid lamellae. Statistical comparison between the different groups of biopsies was performed using Chi² test.

Results

Quantitative analysis of the high performance thin layer chromatography of SC lipids extracted from the non-involved skin of atopic dogs has demonstrated a remarkable decrease in all three protein-bound lipid classes studied, i.e.: ceramides, cholesterol and free fatty acids, when compared to the healthy controls (Fig. 1). Within the free intercellular lipids, a significant decrease was only noted in the ceramide fractions. After 2 months of Megaderm[®]/EFA-Z[®] supplementation, the lipid contents have changed significantly (Figs. 1 and 2). It returned within the control levels for protein-bound cholesterol and fatty acids and, remarkably, for free intercellular ceramides. However, the protein-bound fraction of ceramides, although significantly increased when compared to the situation from before the treatment, remained well below the values found in healthy dogs. Additionally, 2-month supplementation with EFA resulted in a considerable increase in the SC free cholesterol and free fatty acids, exceeding the levels found in both normal dogs and in non-involved atopic skin.

Quantitative analysis of the SC lipids structured in bi-layers was performed using transmission electron microscopy of the ruthenium tetroxide-stained skin biopsies (Fig. 3). In non-involved skin of the atopic dogs, only a small fraction of the first two extracellular spaces of the SC was filled with the lipid lamellae. This was in evident contrast with the situation observed in normal skin of the control dogs, where the lipid lamellae occupied 90% of the area. The treatment of AD dogs with EFA resulted in a highly significant increase in this respect, from 26% to 59%, but the situation after the treatment remained still deficient when compared to the normal ($P < 0.05$).

Discussion

Roughly equimolar proportions of ceramides, cholesterol, and free fatty acids are necessary for building the efficient lipid-dependant permeability barrier in the SC (Elias 2006;

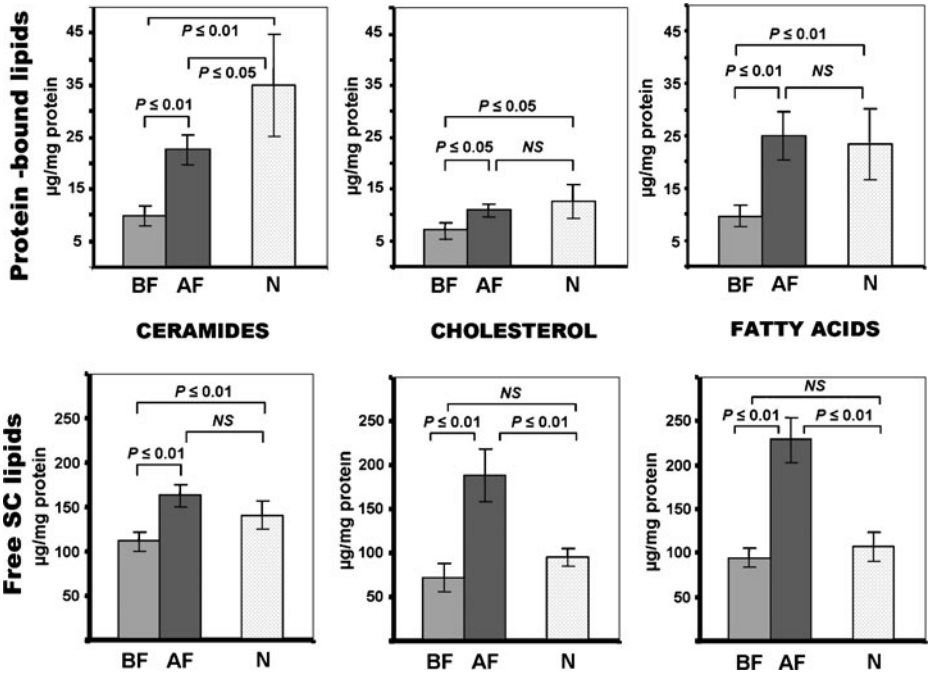


Fig. 1 Densitometry of the SC lipids extracted from non-involved skin of atopic dogs before and after treatment with the EFA supplement. Free and protein-bound lipids were extracted from the SC tape-strips, separated, visualized, and quantified as described in the *Materials and Methods*. The samples of ceramides (A), cholesterol (B), and fatty acids (C) from before (BF) and after (AF) treatment are compared. Atopic dogs show a remarkable decrease in free and protein-bound ceramides before the treatment, compared to normal controls (N). After 2 months of supplementation, free ceramides return to normal but not the cell envelope-bound species. Initially depressed, protein-linked cholesterol and fatty acids return to the normal values after the treatment. EFA supplementation induces also a considerable increase in the free cholesterol and fatty acid fractions. The lipid quantities are expressed in µg per mg of dry weight SC protein used for extraction; mean ± SD; n=5; Mann-Whitney test.

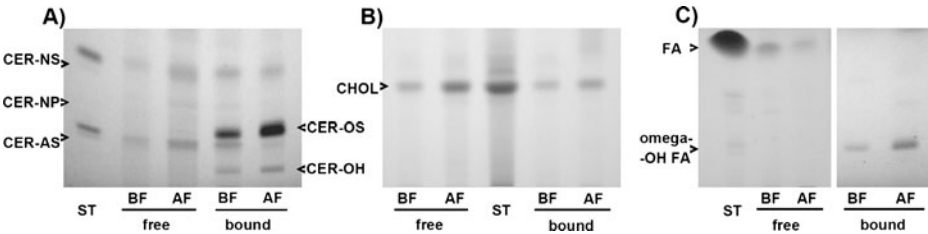


Fig. 2 Representative results of high performance thin layer chromatography of the SC lipids from the non-involved skin of a dog with AD, showing remarkable modifications in the lipid composition after EFA supplementation. Free and protein-bound lipids were extracted from the SC strips, separated and visualized, as described in the *Materials and Methods*. The samples of ceramides (A), cholesterol (B), and fatty acids (C) from before (BF) and after (AF) treatment are compared. There is a visible increase after the treatment in amounts of the extracted free and protein-bound ceramides, as well as free cholesterol and free fatty acids. The composition of visualized ceramide (CER) molecules is as follows: NS = normal fatty acid linked to sphingosine; NP = normal fatty acid linked to phytosphingosine; AS = alpha-hydroxy fatty acid linked to sphingosine; OS = omega-hydroxy fatty acid linked to sphingosine; OH = omega-hydroxy fatty acid linked to 6-hydroxy sphingosine

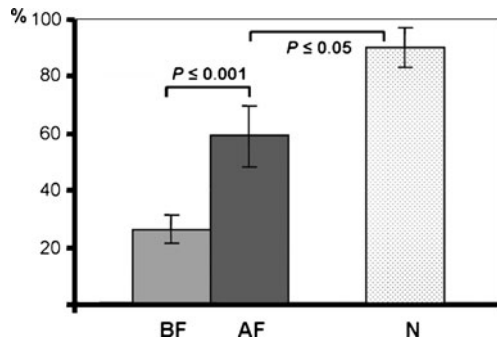


Fig. 3 Quantitative evaluation of the lipids structured in lamellar sheets occupying the first two intercellular spaces of the dogs' SC. Although the treatment with EFA results in a significant increase in the lipid lamellae in non-involved atopic skin (*BF* before; *AF* after), the values reached remain significantly lower than those found in the reference healthy animals (*N*). Each *bar* represents the mean value, *error bars* indicate \pm SD; $n=5$; χ^2 test

Bouwstra et al. 2006). Changes in this delicate balance observed in skin pathology, and which can be reproduced experimentally, lead to the “leaky” SC, with all the functional and clinical consequences (Bouwstra et al. 2006; Holleran and Takagi 2006). In addition, in order to build the barrier, the extracellular lipids have to be correctly structured in lipid bi-layers (Garson et al. 1991; Potts and Francoeur 1991; Pilgram et al. 2001). Lipid envelope composed of a monolayer of omega-hydroxylated ceramide and fatty acid molecules covalently cross-linked to the surface of corneocyte's protein envelope serves as a template for organization of the extracellular lipids and thus is essential for ordinate construction of the SC lipid bi-layers and barrier function (Wertz et al. 1989; Behne et al. 2000; Meguro et al. 2000). Indeed, not only the overall decrease of the SC ceramides (Imokawa et al. 1991; Di Nardo et al. 1998) but also a significant reduction in omega-hydroxylated ceramides has been reported in human AD (Macheleidt et al. 2002). The compositional and structural lipid deficiency in the non-lesional SC of atopic dogs, previously reported and also observed in the present study emerges, therefore, as a plausible constitutive factor leading to the increased skin barrier permeability and, in turn, to the development and maintenance of AD lesions (Inman et al. 2001; Olivry and Hill 2001; Piekutowska et al. 2008; Reiter et al. 2009; Shimada et al. 2009; Popa et al. 2011a, b).

The fact that both the overall lipid quantities and their ultrastructural arrangement in multiple molecular layers increase significantly after supplementation with EFA is noteworthy (Menon 2006). Improvement in the expression of protein-bound ceramides is the most remarkable feature, as it may be responsible for the observed accumulation of the lamellar lipids (Ponec et al. 2000). However, the level of organisation of the lipid layers in the most profound part of the SC after 2 months of EFA supplementation remains far from normal. This may be due to the imperfect proportions between the SC lipids induced by the treatment. Indeed, free fatty acids and cholesterol increase approximately two times more than ceramides in the lipid fraction not bound to proteins, and this is also the case of protein-bound fatty acids. Assessment of the lipid profile in the SC using in parallel high performance thin layer chromatography and transmission electron microscopy can provide valuable data indicating the SC barrier competence in healthy and diseased skin.

Reasons underlying lipid defects in the skin of AD dogs remain unknown but may be related to some constitutive metabolic defect, as they occur preferentially in certain breeds. Sustained EFA supplementation exerts most probably influence on keratinocyte metabo-

lism, fostering production of the barrier lipids (Mao-Qiang et al. 1995). Such a mechanism has already been suggested to explain the beneficial effects of topically applied sphingolipids in canine AD (Piekutowska et al. 2008).

The clinical evolution observed in AD dogs treated with EFA can be at least partially ascribed to the improvement in the composition and structure of the SC lipids (Proksch et al. 2003). The structural and quantitative changes in the SC barrier lipids induced by this feed supplementation in the non-lesional skin suggest an improvement of the barrier function of the epidermis. If this is associated with a better resistance to transcutaneous penetration of foreign agents susceptible of driving atopic inflammatory responses remains to be studied. Based on the obtained results, it would be extremely interesting to perform an additional study in which control dogs, breed and age-paired with the AD group, would receive the Megaderm supplementation. Also, additional evaluation of potential alternate targets of the feed supplementation, other than epidermal ceramides, e.g., eicosanoid synthesis pathway and cytokine production, could be helpful for a better comprehension of the mechanisms involved in the clinically observed improvement.

Acknowledgements This study was supported by the European COST action BM0903 (SkinBAD, skin barrier in atopic dermatitis) and the European Epidermal Barrier Research Network (E²BRN).

Electron microscopy samples were examined at the Centre Technologique des Microstructures (CTμ) de l'Université de Lyon1, La Doua, Villeurbanne, France.

The results reported in this paper have been partially presented at the Sixth World Congress of Veterinary Dermatology, Hong Kong, November 2008 (abstract in *Vet. Dermatol.* 2008; 19 (suppl 1): 68) and at the European Society for Dermatological Research meeting, Helsinki, September 2010 (abstract in *J Invest Dermatol* 130: S13, 2010).

Conflict of interest This study was partially financed by Virbac S.A., France.

References

- Barros Roque J, O'Leary CA, Kyaw-Tanner M et al (2009) Haplotype sharing excludes canine orthologous filaggrin locus in atopy in West Highland White Terriers. *Anim Gen* 40:788–794
- Behne M, Uchida Y, Seki T et al (2000) Omega-hydroxyceramides are required for corneocyte lipid envelope (CLE) formation and normal epidermal permeability barrier function. *J Invest Dermatol* 114:185–192
- Bouwstra JA, Pilgram GSK, Ponc M (2006) Structure of the skin barrier. In: Elias PM, Feingold KR (eds) *Skin barrier*. Taylor & Francis, New York, pp 65–96
- Chervet L, Galichet A, McLean WHI, Chen H, Suter MM, Roosje PJ, Müller EJ (2010) Missing C-terminal filaggrin expression, NFκB activation and hyperproliferation identify the dog as a putative model to study epidermal dysfunction in atopic dermatitis. *Exp Dermatol* 19:e343–e346
- Di Nardo A, Doucet P, Giannetti A et al (1998) Ceramide and cholesterol composition of the skin of patients with atopic dermatitis. *Acta Derm Venereol* 78:27–30
- Elias PM (2006) Improving barrier function. In: Elias PM, Feingold KR (eds) *Skin barrier*. Taylor & Francis, New York, pp 591–600
- Elias PM, Hatano Y, Williams M (2008) Basis for the barrier abnormality in atopic dermatitis: outside-inside-outside pathogenic mechanisms. *J Allergy Clin Immunol* 121:1337–1343
- Favrot C, Steffan C, Seewald W et al (2010) A prospective study on the clinical features of chronic canine atopic dermatitis and its diagnosis. *Vet Dermatol* 21:23–31
- Garson JC, Doucet J, Levèque JL et al (1991) Oriented structure in human stratum corneum revealed by X-ray diffraction. *J Invest Dermatol* 96:43–49
- Griffin CE, DeBoer DJ (2001) The ACVD task force on canine atopic dermatitis (XIV): clinical manifestations of canine atopic dermatitis. *Vet Immunol Immunopathol* 81:255–269

- Hillier A, Olivry T (2004) Spontaneous canine model of atopic dermatitis. In: Chan LS (ed) Animal models of human inflammatory skin diseases. CRC, Boca Raton, pp 353–370
- Holleran WM, Takagi Y (2006) Stratum corneum lipid processing: the final steps in barrier formation. In: Elias PM, Feingold KR (eds) Skin barrier. Taylor & Francis, New York, pp 231–260
- Imokawa G, Abe A, Jin K et al (1991) Decreased level of ceramides in stratum corneum of atopic dermatitis: an etiologic factor in atopic dry skin? *J Invest Dermatol* 96:523–526
- Inman AO, Olivry T, Dunston SM et al (2001) Electron microscopic observations of stratum corneum intercellular lipids in normal and atopic dogs. *Vet Pathol* 38:720–723
- Jakasa I, Koster ES, Calkoen F et al (2011) Skin barrier function in healthy subjects and patients with atopic dermatitis in relation to filaggrin loss-of-function mutations. *J Invest Dermatol* 131:540–542
- Jungersted JM, Scheer H, Mempel M et al (2010) Stratum corneum lipids, skin barrier function and filaggrin mutations in patients with atopic eczema. *Allergy* 65:911–918
- Macheleidt O, Kaiser HW, Sandhoff K (2002) Deficiency of epidermal protein-bound omega-hydroxyceramides in atopic dermatitis. *J Invest Dermatol* 119:166–173
- Mao-Qiang M, Brown BE, Wu-Pong S et al (1995) Exogenous nonphysiologic vs physiologic lipids. Divergent mechanisms for correction of permeability barrier dysfunction. *Arch Dermatol* 131:809–816
- Meguro S, Arai Y, Masukawa Y et al (2000) Relationship between covalently bound ceramides and transepidermal water loss (TEWL). *Arch Dermatol Res* 292:463–468
- Menon GK (2006) What makes a good barrier? Adaptive features of vertebrate integument. In: Elias PM, Feingold KR (eds) Skin barrier. Taylor & Francis, New York, pp 211–222
- Motta S, Monti M, Sesana S et al (1993) Ceramide composition of the psoriatic scale. *Biochem Biophys Acta* 1182:147–151
- Naoi M, Lee YC, Roseman S (1974) Rapid and sensitive determination of sphingosine bases and sphingolipids with fluorescamine. *Anal Biochem* 58:571–577
- Olivry T, Hill PB (2001) The ACVD task force on canine atopic dermatitis: is the epidermal lipid barrier defective? *Vet Immunol Immunopathol* 81:215–218
- O'Regan GM, Kemperman PM, Sandilands A et al (2010) Raman profiles of the stratum corneum define 3 filaggrin genotype-determined atopic dermatitis endophenotypes. *J Allergy Clin Immunol* 126:574–580
- Piekutowska A, Pin D, Rème CA et al (2008) Effects of a topically applied preparation of epidermal lipids on the stratum corneum barrier of atopic dogs. *J Comp Pathol* 138:197–203
- Pilgram GSK, Vissers DCJ, van der Meulen H, Pavel S, Lavrijsen SPM, Bouwstra JA, Koerten HK (2001) Aberrant lipid organization in stratum corneum of patients with atopic dermatitis and lamellar ichthyosis. *J Invest Dermatol* 117:710–717
- Ponec M, Boelsma E, Weerheim A (2000) Covalently bound lipids in reconstructed human epithelia. *Acta Derm Venereol (Stockh)* 80:89–93
- Popa I, Thuy LH, Colsch B et al (2010) Analysis of free and protein-bound ceramides by tape stripping of stratum corneum of dogs. *Arch Dermatol Res* 302:639–644
- Popa I, Remoué N, Thuy LH et al (2011) Atopic dermatitis in dogs is associated with a high heterogeneity in the distribution of protein-bound lipids within the stratum corneum. *Arch Dermatol Res*. doi:10.1007/s00403-011-1120-5
- Potts RO, Francoeur ML (1991) The influence of stratum corneum morphology on water permeability. *J Invest Dermatol* 96:495–499
- Proksch E, Jensen JM, Elias PM (2003) Skin lipids and epidermal differentiation in atopic dermatitis. *Clin Dermatol* 21:134–144
- Reiter LV, Torres SMF, Wertz PW (2009) Characterization and quantification of ceramides in the nonlesional skin of canine patients with atopic dermatitis compared with controls. *Vet Dermatol* 20:260–266
- Sandilands A, Terron-Kwiatkowski A, Hull PR et al (2007) Comprehensive analysis of the gene encoding filaggrin uncovers prevalent and rare mutations in ichthyosis vulgaris and atopic eczema. *Nat Genet* 39:650–654
- Shimada K, Yoon JS, Yoshihara T et al (2009) Increased transepidermal water loss and decreased ceramide content in lesional and non-lesional skin of dogs with atopic dermatitis. *Vet Dermatol* 20:541–546
- Wertz PW, Madison KC, Downing DT (1989) Covalently bound lipids of human stratum corneum. *J Invest Dermatol* 92:109–111
- Willemsse T (1986) Atopic skin disease: a review and a reconsideration of diagnostic criteria. *J Small Anim Pract* 27:771–778